

INTUSSUSCEPTION ULTRASOUND

DATE: ___/___/___

TECH: _____

ID #: _____

PATIENT NAME: _____ DOB: ___/___/___ SEX: M / F

ACUTE HX (location, duration, severity) :

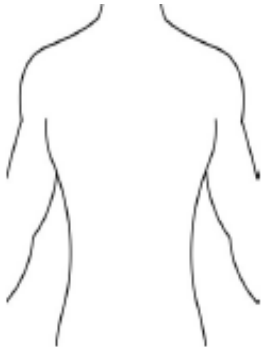
VOMITTING / BLOODY STOOL / FEVER /
PALPABLE ABDOMEN MASS

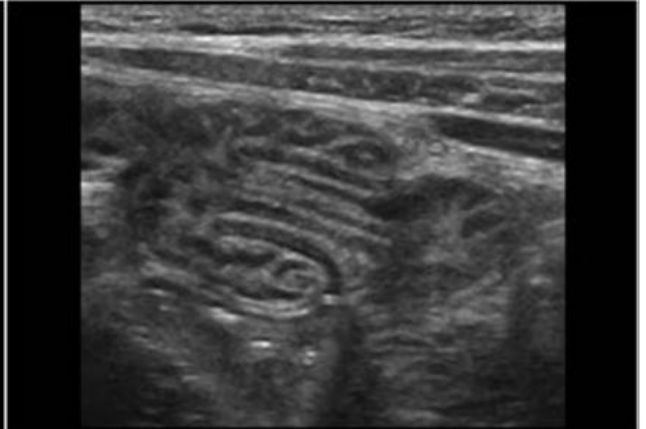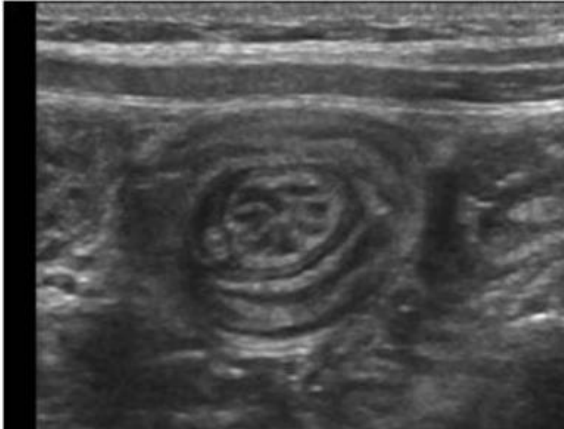CHRONIC HX: _____

Diabetes HTN COPD CHF DVT
Smoking ETOH Obesity Renal Failure

Surgeries: _____

PRIOR: _____ DATE / NONE

US FINDINGS	Size: _____ x _____ x _____ cm	LOCATION: RUQ LUQ RT MID LT MID ABD ABD RLQ LLQ PELVIS MIDLINE	
	Blood flow noted: Yes / No		
	Intussusception: Yes / No		
	Free fluid : Yes / No		



1. Intussusception occurs when bowel prolapses into more distal bowel.
2. Some symptoms patients may present with are colicky abdomen pain, vomiting and bloody stool.
3. A palpable abdominal mass may be noted.
4. In longitudinal, the mass will appear with an echogenic center with hypoechoic layers on each side.
5. In longitudinal, intussusception can have the appearance of a pseudokidney or sandwich sign.
6. In transverse, the mass will appear as alternating hypoechoic and hyperechoic rings (target sign)

Tech Summary:

